Case report

Gram variable *Streptococcus dysgalactiae* subsp. *equisimilis* recovered from a suppurative peritoneal effusion of a dog

Georgios Meletis[1], Christina Marouda[1], Georgios Tzimagiorgis[2], Maria Chatzidimitriou[3], Ioannis Rintis[4], Dimitrios Chatzidimitriou[1,5]

[1]*Labnet laboratories, Thessaloniki, Greece*
[2]*Laboratory of Biological Chemistry, School of Health Sciences, Medical Department, Aristotle University of Thessaloniki, Greece*
[3]*Biomedical Sciences Alexander Campus, International Hellenic University, Thessaloniki, Greece*
[4]*Private veterinary practice, Giannitsa, Greece*
[5]*Laboratory of Microbiology, Medical School, Aristotle University of Thessaloniki, Greece*

DOI: https://doi.org/10.5281/zenodo.10074769

Corresponding author
Georgios Meletis MD, MSc, PhD
Labnet laboratories, Agiou Dimitriou str. 161
54638, Thessaloniki Greece
Tel: +306974282575
fax: +302310301340
E-mail: meletisg@hotmail.com

Key words
Streptococcus dysgalactiae; Gram variability; group C Streptococcus; peritoneal effusion

Streptococcus dysgalactiae is a Gram positive pathogenic species for both humans and animals presenting a clinical picture often similar to that of *Streptococcus pyogenes*.[1] Due to heterogeneity issues, it was divided into two subspecies: *S. dysgalactiae* subsp. *equisimilis* and *S. dysgalactiae* subsp. *dysgalactiae*. Further genetic heterogeneity, leading to phenotypic variabilities (hemolysis type, C or G Lancefield group) has been reported since for *S. dysgalactiae* subsp. *equisimilis*, thus questioning the current subspecies identification criteria.[1]

On 12 June 2020, a suppurative peritoneal effusion of a dog was sent to our reference laboratory for further evaluation. The dog was a two-year-old female Dogo Argentino that presented in a private veterinary practice with progressive anorexia, lethargy and abdominal distention. A number of abnormalities of blood and serum biochemical parameters were observed including mild normocytic normochromic anemia (28.2% HCT), a mild increase in glucose concentration (123mg/dL), and a moderate to marked increase in creatinine (1.43 mg/dL), urea (33.2 mg/dL) and amylase (2503 U/L). Abdominal ultrasonography revealed peritoneal effusion. Abdominocentesis yielded a large amount of a yellow to cloudy, turbid fluid with 32 K/μL nucleated cells, and a protein concentration of 3.5 g/dL.

Cytology of direct and sediment smears revealed the presence of inflammatory cells and surprisingly, abundant negatively-stained Streptococci (Gram staining). A catalase negative coccus was isolated after 24h incubation onto blood agar plate. The isolate belonged to Lancefield group C and was molecularly characterized using PCR amplification, cloning and sequencing of the 16S rRNA gene. Comparison of the 16S rRNA nucleotide sequence using the BLASTN algorithm, revealed 100% sequence identity with *S. dysglactiae* subsp. equisimilis. It presented however, an unusual Gram stain profile, appearing predominantly as Gram negative (Fig. 1). The Gram staining procedure was repeated three times by three different operators, using three different Gram stain kits, in two different laboratories obtaining the same Gram variable result. It was susceptible to β-lactams, macrolides, and fluoroquinolones using both EUCAST and veterinary CLSI criteria.

Our finding is rare and supports the proposal for further investigation regarding the genetic and phenotypic variability of *S. dysglactiae* subsp. *equisimilis*.[1] Following our results, an exploratory celiotomy was performed. The entire omentum had a yellowish color and diffuse peritonitis and suppurative peritoneal effusion were also observed. The inciting source of the infection was a perforating foreign body in the gastrointestinal tract which was removed along with necrotic debris and fluid. The abdominal cavity was lavaged with sterile physiological solution and the patient was discharged with ongoing administration of antibiotics. Two months postoperatively, the owner reported good health condition of the animal.

Figure 1

Microscopic images of *Streptococcus dysglactiae* subsp. *equisimilis* showing Gram variability and stained mostly Gram negative. Panel A&B: Gram stain of the peritoneal effusion (x100); Panel C&D: Gram stain of the bacterial culture (x100).

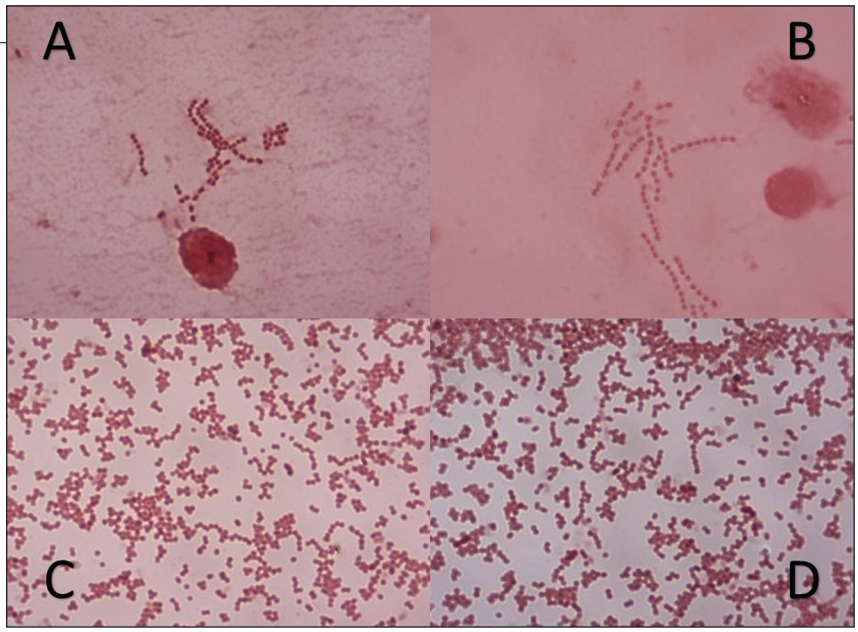

Περίληψη

Απομόνωση Gram μεταβλητού *Streptococcus dysgalactiae* subsp. *equisimilis* από πυώδη περιτοναϊκή συλλογή σκύλου

Γεώργιος Μελέτης[1], Χριστίνα Μαρούδα[1], Γεώργιος Τζημαγιώργης[2], Μαρία Χατζηδημητρίου[3], Ιωάννης Ρίντης[4], Δημήτριος Χατζηδημητρίου[1,5]
[1]*Εργαστήρια "Labnet", Θεσσαλονίκη, Ελλάδα*
[2]*Εργαστήριο Βιολογικής Χημείας, Τμήμα Ιατρικής, Σχολή Επιστημών Υγείας, Αριστοτέλειο Πανεπιστήμιο Θεσσαλονίκης, Ελλάδα*
[3]*Βιοϊατρικές Επιστήμες, Αλεξάνδρειο Campus, Διεθνές Πανεπιστήμιο της Ελλάδας, Θεσσαλονίκη, Ελλάδα*
[4]*Ιδιωτικό Κτηνιατρικό Ιατρείο, Γιαννιτσά, Ελλάδα*
[5]*Εργαστήριο Μικροβολογίας, Ιατρική Σχολή, Αριστοτέλειο Πανεπιστήμιο Θεσσαλονίκης, Ελλάδα*

Λέξεις κλειδιά
Streptococcus dysgalactiae; Gram μεταβλητότητα; group C Streptococcus; περιτοναϊκή συλλογή

References

1. Ciszewski,M, Zegarski K, Szewczyk EM. Streptococcus dysgalactiae subsp. equisimilis Isolated From Infections in Dogs and Humans: Are Current Subspecies Identification Criteria accurate? Curr Microbiol 2016; 73: 684–688.